



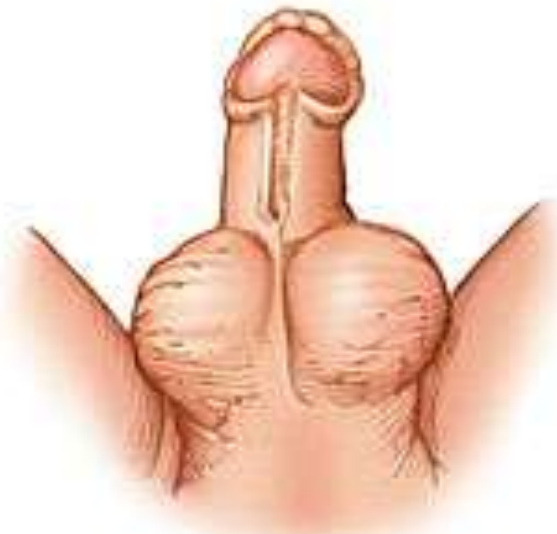HYPOSPADIAS

INTRODUCTION

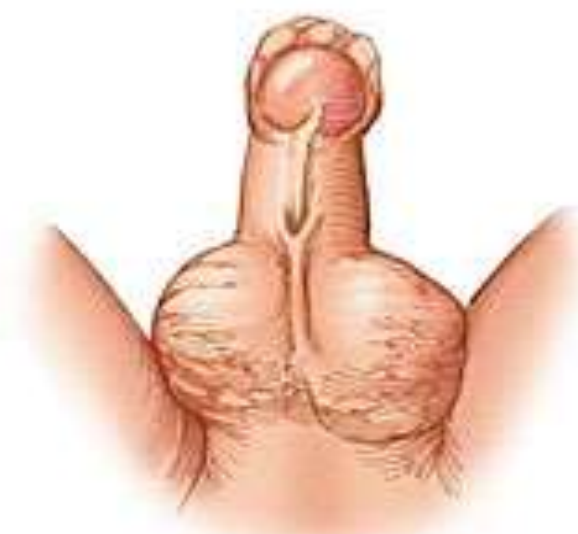- **Hypospadias** is a birth defect of the urethra in the male that involves an abnormally placed urinary meatus (opening).
- Instead of opening at the tip of the glans of the penis, a hypospadic urethra opens anywhere along a line (the *urethral groove*) running from the tip along the underside (ventral aspect) of the shaft to the junction of the penis and scrotum or perineum.

DEFINITION

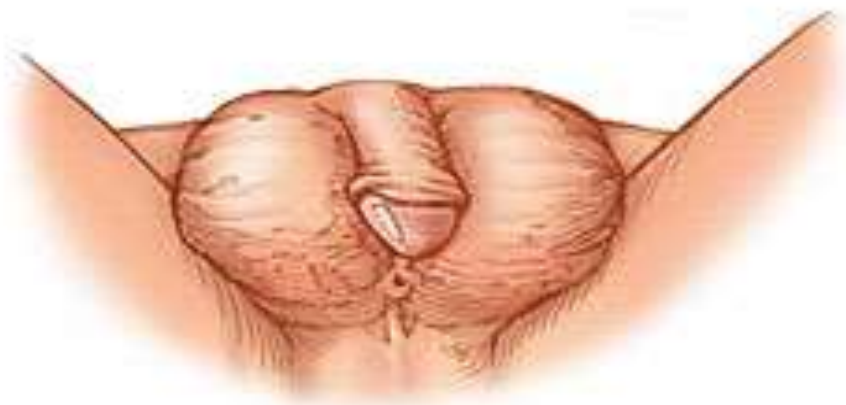- Hypospadias is an abnormality of anterior urethral and penile development in which the urethral opening is ectopically located on the ventrum of the penis proximal to the tip of the glans penis.
- Hypospadias is a common birth (congenital) defect in which the opening of the urethra is on the underside, rather than at the end, of the penis.



Penile hypospadias

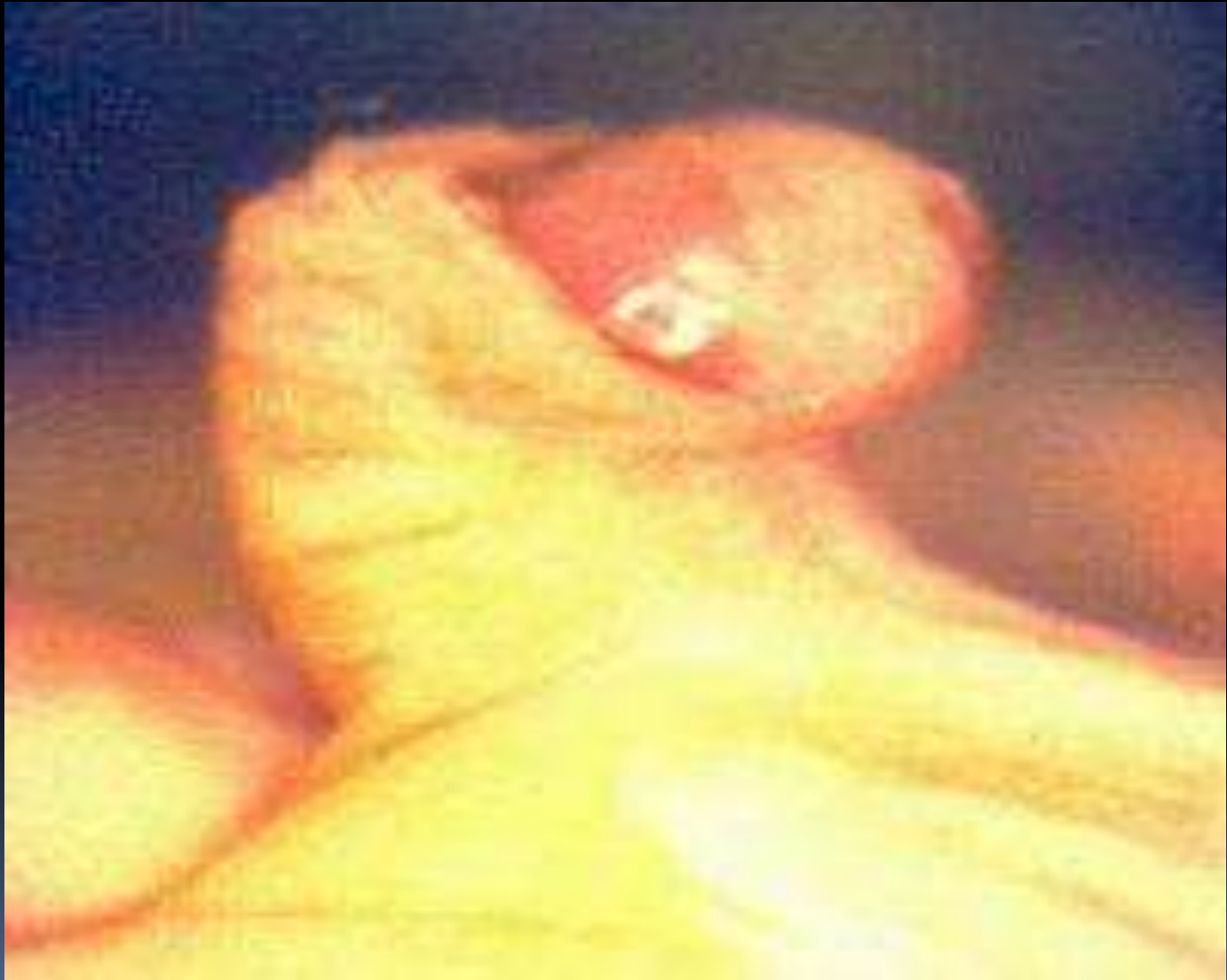

**Penilescretal hypospadias
(with chordee)**

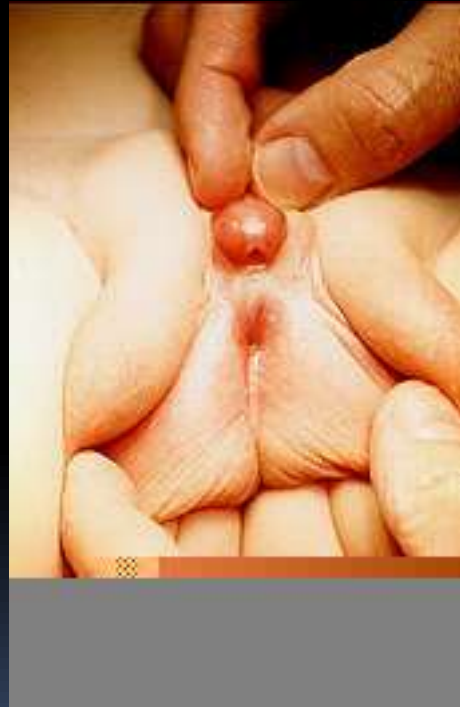

Scrotal hypospadias

CHORDEE



PENOSCROTAL HYPOSPADIAS





INCIDENCE

- Hypospadias occurs in about 1 in 100 to 1 in 200 male children.
- 



ETIOLOGY


- **Genetic factors** –common among monozygotic twins
- **Endocrine factors**- A decrease in available androgen or an inability to use available androgen appropriately or defect in testicular testosterone biosynthesis
- **Environmental factors** -ingested as pesticides on fruits and vegetables,

Signs & Symptoms

- opening of the urethra is under the penis rather than at its tip.
- downward curve (chordee) of the penis during an erection.
- Abnormal spraying of urine
- Having to sit down to urinate
- Malformed foreskin that makes the penis look "hooded"





DIAGNOSTIC EVALUATION

- Physical examination - focusing on the meatal location, glans configuration, skin coverage, and chordee.
 - Prenatal ultrasonography
- 

MANAGEMENT

- Infants with hypospadias should not be circumcised.
- The foreskin should be preserved for use in later surgical repair.
- Surgery is usually done before the child starts school. /or done before the age of toilet training
- Today, most urologists recommend repair before the child is 18 months old.
- During the surgery, the penis is straightened and the hypospadias is corrected using tissue grafts from the foreskin.
- The repair may require multiple surgeries.

- 
- More severe chordee may require grafting of the ventral corporal bodies using synthetic, animal (small intestinal subunit), cadaveric, or autologous tissues (tunica vaginalis or dermal grafts) to avoid excessive shortening of penile length.
 - Urethroplasty . The urethra may be extended using various techniques- primary tubularizations, tissue grafting techniques, or meatal advancement procedures.

- 
- To protect the newly constructed urethra (neourethra) the urine is usually diverted with a stent (a silastic tube through the neourethra) or catheter
 - Glansplasty
 - Adjuvant hormonal therapy .
 - Presurgical treatment with testosterone injections or creams, as well as HCG injections, has been used to promote penile growth

Nursing Management


- Newborn examination
- Assess urinary functions
- Preoperative teaching .
- Pressure dressing
- Catheter or stent care
- Fluid intake-to maintain hydration & free flow of urine
- Monitor V/S,& Urinary patterns
- Postoperative prophylactic antibiotics
- Diversional activities
- Analgesics
- Play therapy

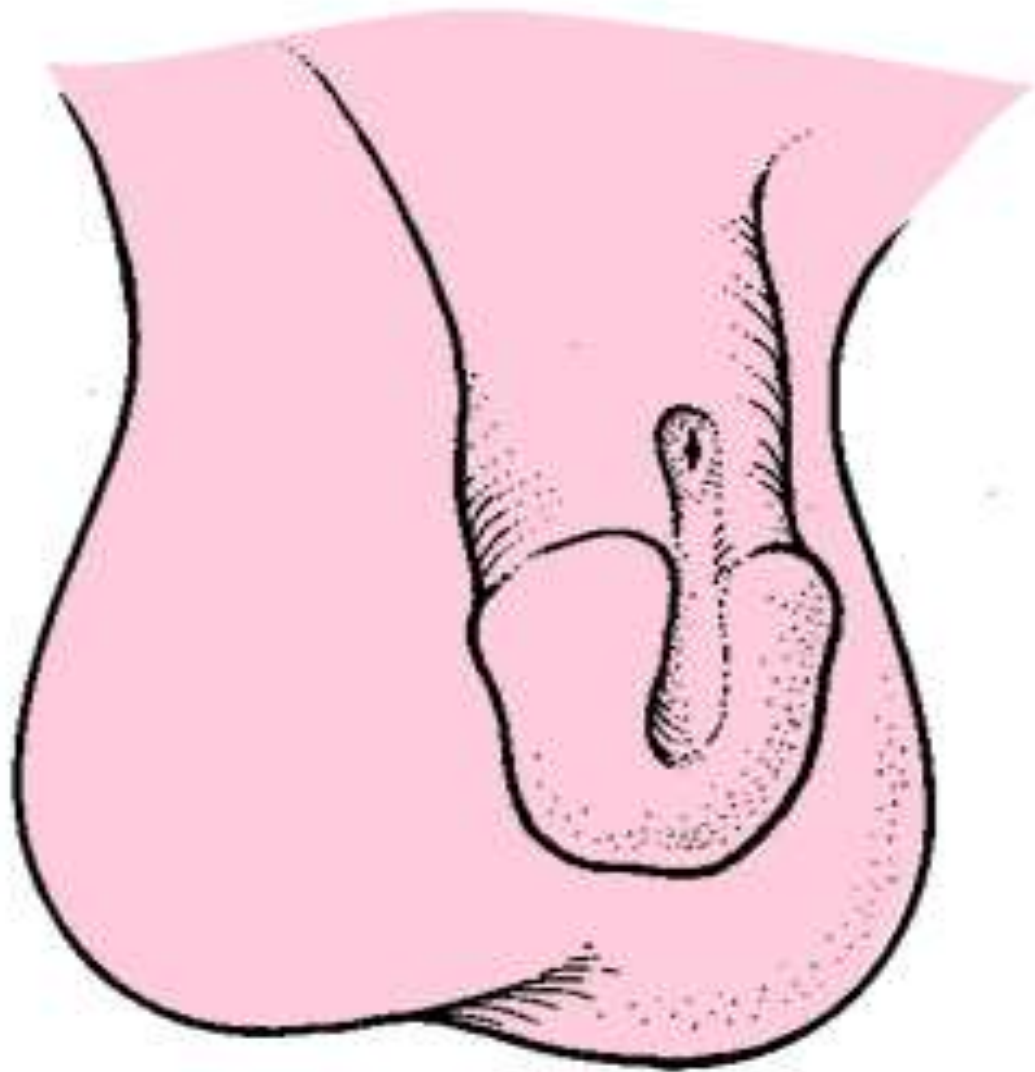


EPISPADIAS




INTRODUCTION

- An **epispadias** is a rare type of malformation of the penis in which the urethra ends in an opening on the upper aspect (the dorsum) of the penis.
- 






INCIDENCE

- It occurs in around 1 in 1,20,000 male and 1 in 5,00,000 female births.
- 



ETIOLOGY

- Failure of midline penile fusion during embryogenesis
 - Defective migration of the genital tubercle primordii to the cloacal membrane
 - Chemical intake of the pregnant mother
 - Viral infection during pregnancy
- 

SIGNS & SYMPTOMS


- Abnormal opening from the joint between the pubic bones to the area above the tip of the penis
- Backward flow of urine into the kidney (reflux nephropathy)
- Short, widened penis with an abnormal curvature
- Urinary tract infections
- Widened pubic bone

DIAGNOSTIC EVALUATION

- Blood test to check electrolyte levels
- Intravenous pyelogram (IVP), a special x-ray of the kidneys, bladder, and ureters
- MRI and CT scans, depending on the condition
- Pelvic x-ray
- Ultrasound of the urogenital system




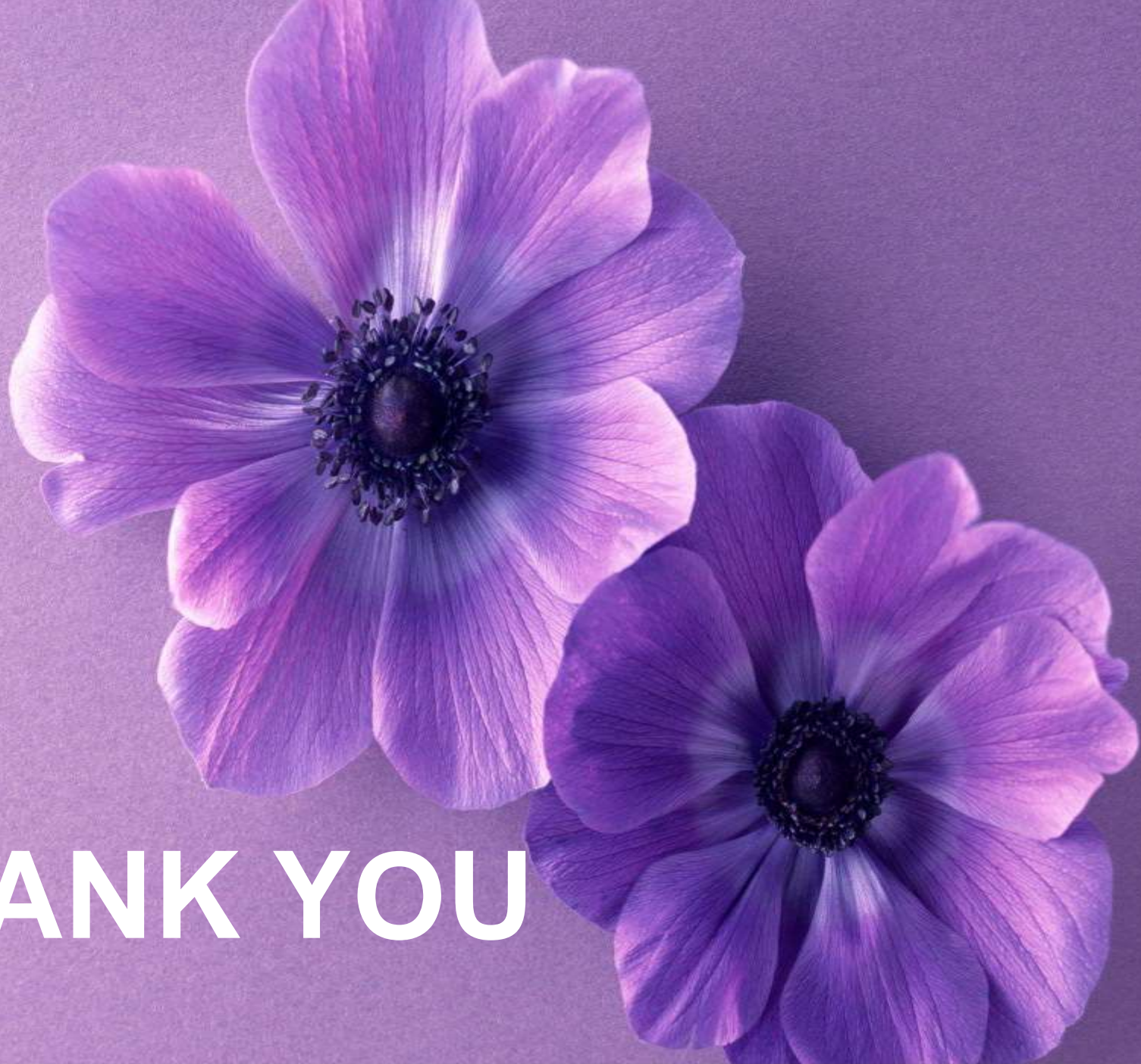MANAGEMENT

- Includes reconstruction of the urethra, closure of the penile shaft and mobilization of the corpora
- 



NURSING MANAGEMENT

- Wound Dressing
 - Psychological support
 - Regular follow up
 - Catheter care
 - Positioning
 - Genital hygiene
- 



THANK YOU

Complications

Immediate postoperative complications

- Local edema and blood spotting
- Postoperative bleeding
- Infection.
- Long-term complications
- Fistula: Urethrocutaneous fistulization
- Meatal stenosis, or narrowing of the urethral meatus,
- Urethral stricture
- Urethral diverticula
- UTI
- Infertility



COMPLICATIONS

- Persistent urinary incontinence
 - Upper urinary tract (ureter and kidney) infection
 - Infertility
 - Depression and psycho-social complications
 - Sexual dysfunction
- 