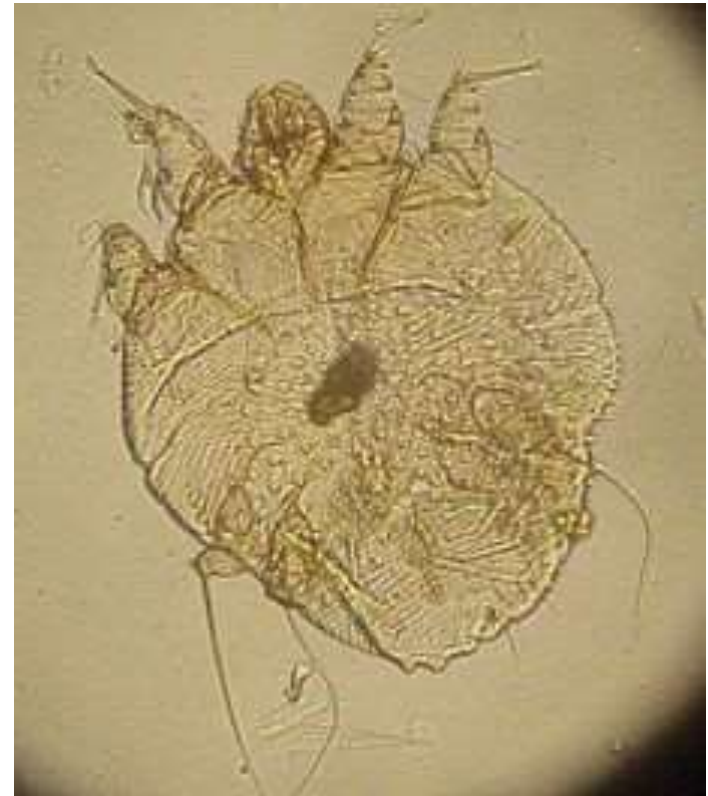


DISORDERS OF SKIN



SCABIES



DEFINITION

- ▶ Scabies is a skin disease commonly found among school children, produced by the burrowing action of a parasite insect mite (*Sarcoptes scabiei*) in the epidermis. It results in irritation and formation of burrows, vesicles and pustules.

CAUSATIVE ORGANISM:

- ▶ *Sarcoptes scabiei*

TRANSMISSION:

- ▶ Direct skin to skin contact with infected persons or indirect contact of clothing and bed linen.
- ▶ It occurs in all socio-economic group regardless of standard of personal hygiene.

INCUBATION PERIOD:

4 to 6 weeks.



CLINICAL MANIFESTATIONS:

- ▶ Itching-primary symptom
- ▶ Followed by Skin lesions as papules and vesicles
- ▶ Burrow, gray or white tortuous threadlike line, between the fingers, in wrist and in axillary or buttock folds.
- ▶ Skin lesions may found on belt line, on male genitalia, female breast, on knees, elbows and ankles, or any part of body, face, neck and scalp. On trunk and groins, found as reddish nodules.
- ▶ Vesicles on palms and soles.
- ▶ Warm and moist areas generally affected.

Contd...

CLINICAL MANIFESTATIONS:

- ▶ Superadded infection of lesions are common and may causes pustules and crust.

COMPLICATION:

- ▶ Acute nephritis

MANAGEMENT:

- ▶ Management is done with application of **scabicide agent**.
- ▶ Commonly used scabicial is 25% Benzyl Benzoate diluted in calamine or water.
- ▶ In case of small children it is applied all over the body from neck to toes after preliminary bath and removed after 24hours.


Contd...

MANAGEMENT

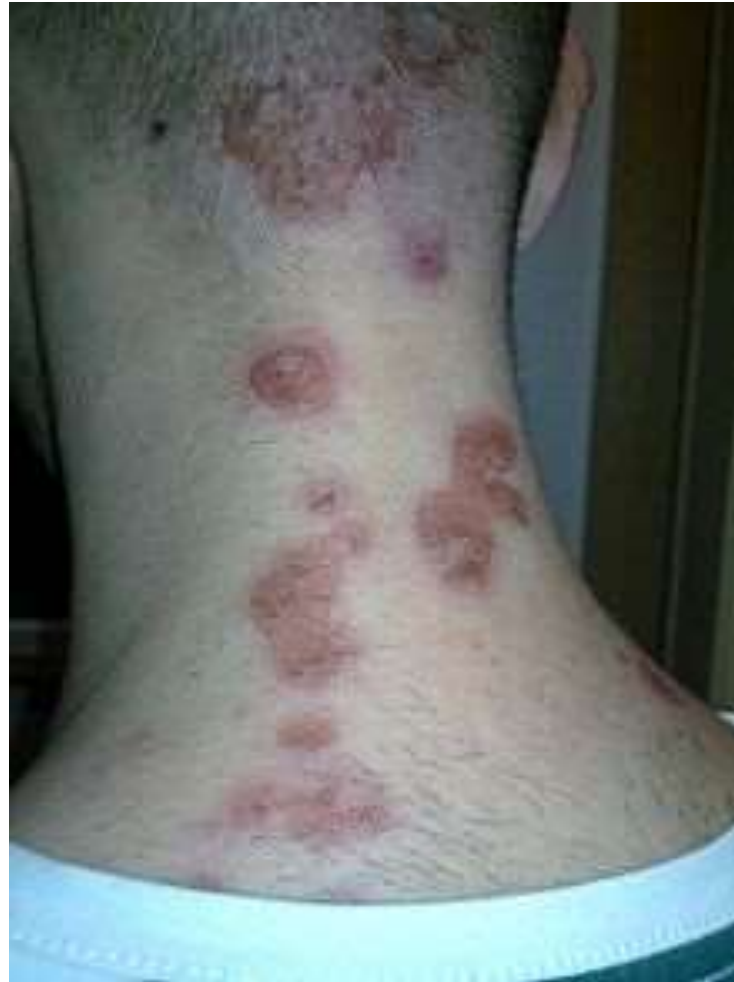- ▶ Best scabicide is 5% permethrin cream- used for infants over 2months and children.
- ▶ Permethrin should be removed by bathing after 8 to 14 hours of application.
- ▶ Other scabicides are: lindane 1%, crotamitone etc.
- ▶ Lindane should be removed after 8 to 12 hours and crotamitone after 48hours of application.
- ▶ Second time application of scabicide may be necessary on next day or after 1week.
- ▶ Treatment with suitable anti-microbial drugs.
- ▶ Anti-histamine drugs may be given if itching continues 2-3weeks after therapy.
- ▶ Steroids may be needed for some children.

Contd...

MANAGEMENT

- ▶ Protective gloves should be used during application of scabicide.
 - ▶ All household and close contacts should receive prophylactic treatment with scabicide on same time, even if they do not have any skin lesions.
 - ▶ After treatment, all clothing, linen and towel should be boiled, sun dried and ironed to kill mites.
 - ▶ Side –effects of therapy should be assessed and necessary treatment to be given.
- 

IMPETIGO



DEFINITION

- ▶ Impetigo is the most common bacterial skin infection characterized by formation of vesicles, pustules, crusts and bullae.

CAUSATIVE ORGANISM:

- ▶ Staphylococcus aureus
- ▶ Streptococcus pyogenes.

INCIDENCE:

- ▶ Common in children below 10 years of age with poor personal hygiene.

TRANSMISSION: spreads by close contact.

PORTAL OF ENTRY: Skin abrasion

INCUBATION PERIOD: 10days


CLINICAL MANIFESTATIONS:

- ▶ Appearance by pink-red macules which become vesicles, rupture to develop crusts and leave temporary superficial erythematous area.
- ▶ Bullous lesions may develop anywhere in the body, commonly on face, axilla, groin.
- ▶ Large thin-roofed blisters break to form thin light brown crusts.
- ▶ Crusted lesions appear with thick yellow crusts
- ▶ Pruritus
- ▶ Lymph gland enlargement
- ▶ Autoinoculation is major cause of spreading of infection

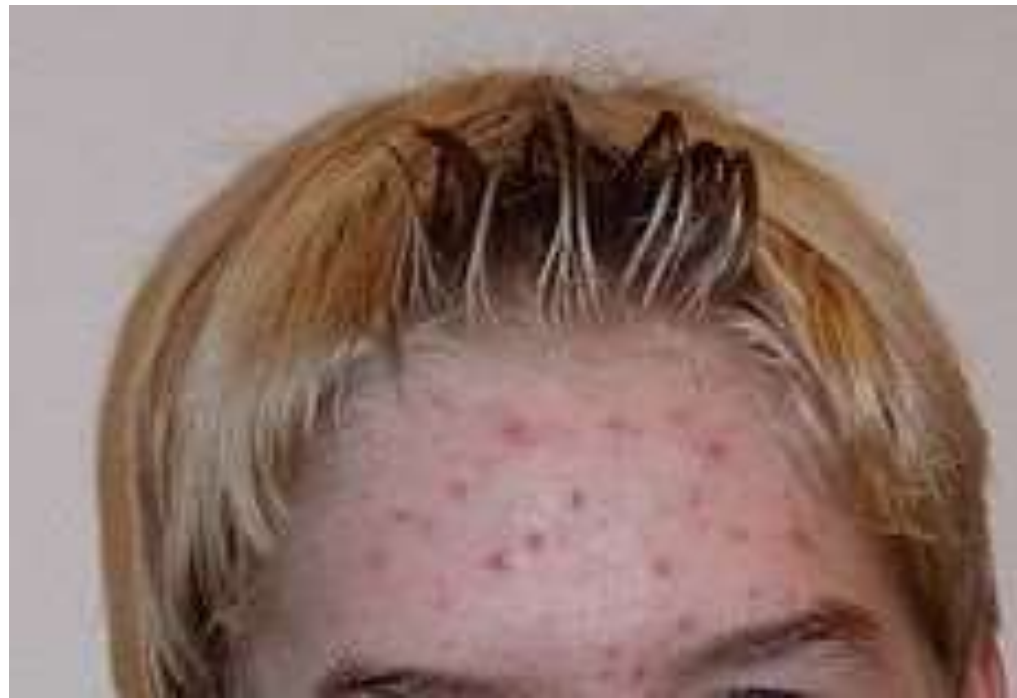MANAGEMENT:

- ▶ Done by gentle washing of affected area with soap and water thrice a day.
- ▶ Removal of crusts and debris by normal saline or condy's lotion (potassium permanganate solution).
- ▶ Application of topical anti-bacterial and systemic antibiotics- cephalosporins, erythromycin.
- ▶ Close contact with other children should be avoided to prevent spread of infection.
- ▶ Autoinoculation should be prevented by frequent hand washing, short nails, daily soap-water bathing, regular laundering of contaminated towel, linen clothing.


COMPLICATIONS:

- ▶ Cellulitis
 - ▶ Osteomyelitis
 - ▶ Septic arthritis
 - ▶ Pneumonia
 - ▶ Septicemia.
 - ▶ Streptococcal infection can cause scarlet fever, lymphangitis, lymphadenitis.
 - ▶ Post-Streptococcal acute glomerulonephritis may occur due to infection by nephritogenic strains.
- 


ACNE



DEFINITION

- ▶ Acne is an inflammatory skin disease manifested as pleomorphic eruptions usually seen over face, trunk and rarely on arms, legs and buttocks.
 - ▶ It is most commonly found in adolescence and rarely in infancy and childhood.
- 


CAUSES OF ACNE

- ▶ Children with greasy scalp
 - ▶ Dandruff
 - ▶ Seborrhea
 - ▶ Increased production of sebum, due to hormonal response
- 

CLINICAL MANIFESTATIONS

- ▶ Initial lesions are found as white heads or blackheads (comedones).
- ▶ Then after 2-3years the classical signs of acne are seen.
- ▶ Comedones are formed due to lack of essential fatty acids and linoleic acid in skin surface lipids.
- ▶ Colonization of micro-organisms leads to inflammation of comedones.
- ▶ The blackheads may be infected with *Staphylococcus epidermidis* or *Propionibacterium acnes*, which leads to formation of papules and pustules.
- ▶ Deeper lesions may form nodular cysts and scarring.


VARIETIES OF ACNE

- ▶ Acne vulgaris
 - ▶ Infantile acne
 - ▶ Steroid acne
 - ▶ Halogen acne
 - ▶ Topical acne
 - ▶ Acne conglobata
 - ▶ Pomade acne
- 

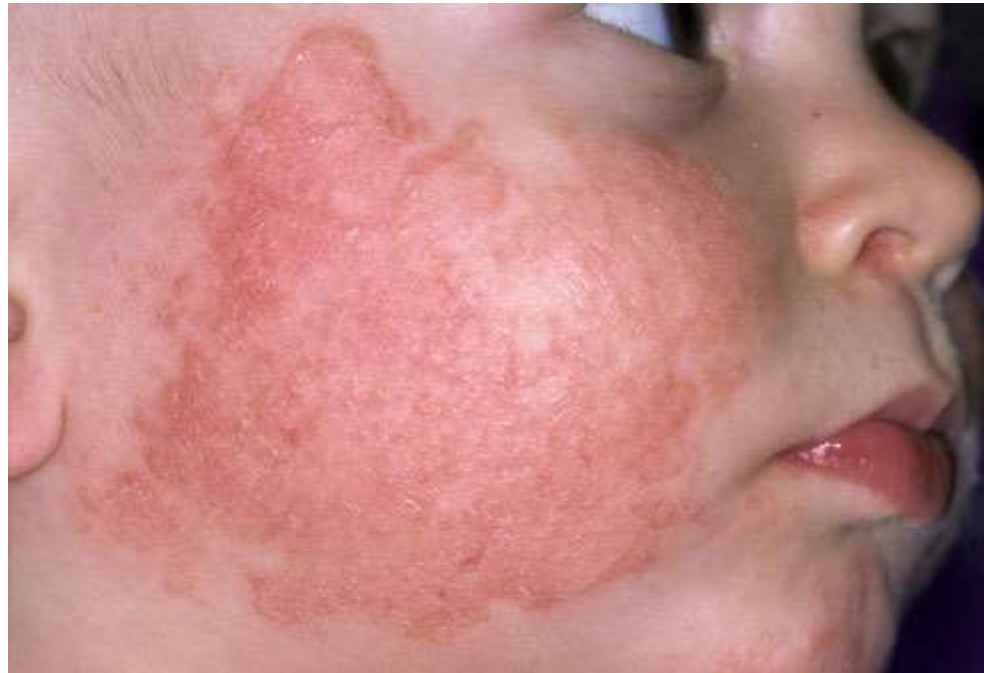MANAGEMENT

- ▶ Treatment done with adequate explanation of cause of condition.
- ▶ Psychological preparation of child for adolescence.
- ▶ Information given about harmful effects of use of cosmetics, hair preparations, facial manipulations and frequent cleansing.
- ▶ Topical application of clindamycin or erythromycin for several weeks gives better results.
- ▶ Benzyl peroxide gel or cream can be used to reduce number of comedones.
- ▶ Other useful agents are azaleic acid, retinoic acid, sulfur, salicylic acid and resorcinol.
- ▶ Systemic antibiotics and vitamin 'A' may be helpful.


Contd....

- ▶ Physical therapy with ultra violet light may be effective. CO₂, or snow or cold water will have good effect.
 - ▶ Surgical management may be done with round extractions of open and closed comedones, needle aspirations or nodulocystic lesions, steroid injections and cosmetic surgery for scarring.
- 


ATOPIC DERMATITIS



DEFINITION

- ▶ Atopic dermatitis is also known as infantile or childhood eczema.
 - ▶ It is usually related with allergic reaction and characterized by erythema, edema, intense pruritus, exudation, lichenification, crusting and scaling.
- 

CAUSES

- ▶ It may be associated with allergic rhinitis (hay fever)
 - ▶ Asthma
 - ▶ Immunodeficiency
 - ▶ Hereditary
 - ▶ Psychogenic
 - ▶ IgE mediated reaction due to immune system abnormalities as deficient suppressor T cell functions.
- 

TYPES WITH CLINICAL MANIFESTATIONS

In early months of life- seborrheic dermatitis.

Infant presents with:

- ▶ Erythematous squamous patches over scalp
- ▶ Behind the ears
- ▶ Around nose
- ▶ Buttocks
- ▶ Genitalia

This condition usually resolves in 4 to 6 weeks.

But in some infants, this condition may progress to infantile eczema.

Contd...

TYPES WITH CLINICAL MANIFESTATIONS

Infantile eczema is characterized by:

- ▶ Rosy erythema over cheeks
- ▶ Fissuring of skin fold behind the ears
- ▶ Soddening of neck folds
- ▶ Dryness and scaling of extensor surfaces of arms, wrists and legs
- ▶ Desquamation
- ▶ Papule formation
- ▶ Crusting

Itching and scratching lead to excoriation and superadded infection with bacteria or fungus.

This condition recovers in majority of cases within 1 or 2 years.

But in few cases may continue with remissions and exacerbations.

Contd...

TYPES WITH CLINICAL MANIFESTATIONS

- ▶ Infantile eczema may continue after 1 or 2 years of age or found as late onset after 1 year of age. Then it is termed as **late onset atopic eczema or Flexural eczema.**

It is characterized by:


- Lesions over flexures of elbows and knees, anterior of neck and front part of ankles.
- The lesions are erythematous, scaling and with lichenification.

Contd....

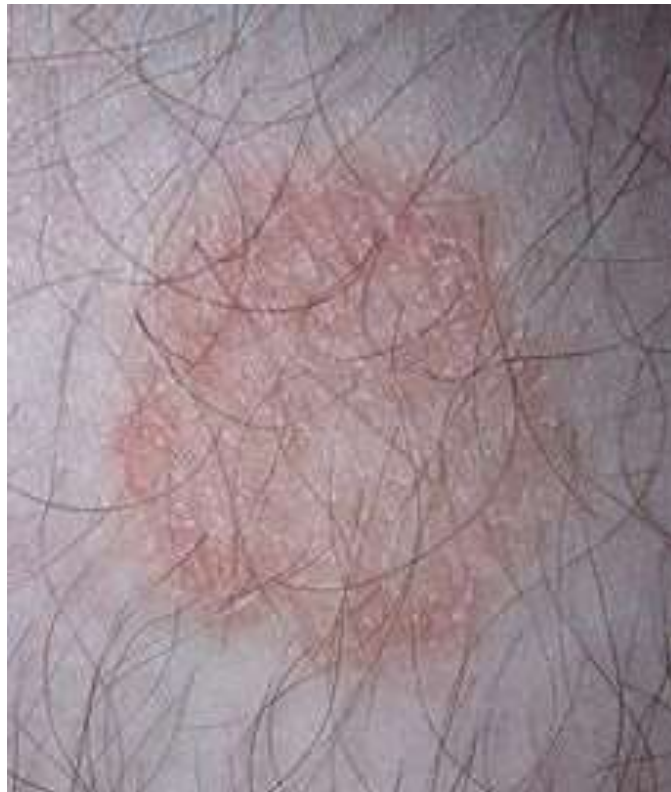TYPES WITH CLINICAL MANIFESTATIONS

- ▶ Atopic dermatitis may also present as coin-shaped vesicular lesions with severe pruritis and known as **nummular eczema**.
- ▶ Another form of Atopic dermatitis is found as **Pityriasis alba** with hypo pigmented patches over face.


MANAGEMENT:

- ▶ Topical applications of steroids, antibiotics, sodium fucidate and anti histaminic drugs.
 - ▶ Systemic antibiotic therapy for 7 to 10 days is useful in active disease.
 - ▶ Other supportive measures- gentle bathing with small liquid antiseptic soap, short nails, avoidance of scratching and allergens (dust, nylon, irritating soap, cosmetics, feather, animal danders, etc).
 - ▶ Dietary intake of fish oil containing omega-3 fatty acid shows favorable results.
- 

DERMATOPHYTOSIS (RINGWORM INFECTIONS)



DEFINITION


- ▶ Dermatophytes are aerobic fungi present in the soil.
 - ▶ Dermatophytosis is also known as ringworm infections, a highly specialized fungal infections of skin and its appendages.
 - ▶ It may be superficial or deep. Depending upon the involved part of the body different terms are used.
- 

TYPES


- ▶ The common ringworm (Tinea) infections are:
 1. Tinea capitis- fungal infection of the scalp due Trichophyton or Microsporum.
 2. Tinea corporis- fungal infection of glabrous skin usually due to Trichophyton or Microsporum.
 3. Tinea cruris- fungal infection in the crural or perineal folds, extending upto upper inside of the thigh and caused by epidermophyton.

Contd...

TYPES

4. Tinea pedis (athletes's foot)- a chronic superficial fungal infection of foot, especially between the toes and on the soles due to Trichophyton or Epidermophyton.
 5. Tinea unguium (onychomycosis)- fungal infection of nails caused by Trichophyton or Epidermophyton.
 6. Tinea versicolor- Achronic non-inflammatory usually asymptomatic disorder due to Pityrosporum orbiculare, marked only by multiple macular patches on the skin.
- 

SPREAD OF INFECTION

- ▶ These infections spread from one child to another child by direct contact or through common use of towels, pillows, combs, hair brush, etc.
 - ▶ Household pets like cats and dogs also can be source of these infections.
- 

TINEA CAPITIS

Incidence-

- ▶ Found in children between 3 to 10 years of age.

Symptoms-

- ▶ Lesions appear on the scalp as round seborrhea like scaly patches with loss of hair (alopecia) and breakage of hair.
- ▶ Pruritus
- ▶ A kerion, an inflammation, that produces edema, pustules and granulomatous swelling, may develop with oozing.


Diagnosis-

- ▶ Examining the scraping of scalp or hair.

Contd.....

TINEA CAPITIS

Treatment-

- ▶ Oral administration of Griesofulvin 15-20mg/kg/day for 5-7days.
 - ▶ Topical administration of anti fungal cream may be effective.
 - ▶ Selenium sulfide lotion can be used twice per week.
 - ▶ Clotrimazole, tolnaftate etc can be used as cream or lotions.
- 

TINEA CORPORIS

Symptoms-

- ▶ Multiple red scaly round patches studded with minute vesicles on any part of the body.
- ▶ Patches enlarge at the periphery and healing occurs at the center giving a characteristic circular shape with pale center and raised edges.
- ▶ Itching
- ▶ Secondary bacterial infections and allergic reactions may occur.


Diagnosis-

- ▶ presence of fungus in the skin scrappings.

Contd...

TINEA CORPORIS

Treatment-

- ▶ Application of calamine lotion and mild fungicides.
 - ▶ Griseofulvin is administered in severe generalized and resistant cases.
 - ▶ Tolnaftate (Tinaderm) is used effectively for this infection.
- 

TINEA CRURIS (Jock itch)

Incidence-

- ▶ Ringworm infection of genitocrural region is found in obese male children.

Symptoms-

- ▶ Lesions are symmetrical, demarcated with well defined border.
- ▶ Itching

Treatment-

- ▶ Griseofulvin or Tolnaftate topical applications.
- 

TINEA PEDIS

Symptoms-


- ▶ Fungal infection of feet involving interdigital clefts of toes and soles found as fissures or macerations.
- ▶ It may be found on the plantar surface of the feet as vesicular patches.
- ▶ Secondary infection
- ▶ Marked itching
- ▶ Bad odour

Contd...



TINEA PEDIS


Treatment-

- ▶ Antifungal agent, aluminium chloride and gentian violet.
 - ▶ Amorolfine spray can be used daily for 3 to 6 weeks.
 - ▶ The web space between toes to be kept dry.
- 

TINEA UNGUIUM

- ▶ It is a chronic and resistant type of fungal infection affecting nails.

Treatment:-

- ▶ Requires treatment for long period.
 - ▶ Griseofulvin or other antifungal agents can be applied for 3 to 4 months for finger nails and 6 to 12 months for toe nails.
 - ▶ Newly available topical preparation such as ciclopirox and natifine can be used for better penetration in the nails.
- 

TINEA VERSICOLOR (ptyriasis)

Incidence-

- ▶ Mild and common found in moist and warm climates.

Cause of infection-

- ▶ It is a superficial infection caused by *Microsporum furfur*.

Symptoms-

- ▶ Presents as yellowish-brown macules.
- ▶ Later, hypo pigmented lesions are found usually on face, neck, arms and trunk.

Contd...



TINEA VERSICOLOR (ptyriasis)

Diagnosis-

- ▶ Scrappings from the lesions.

Treatment-

- ▶ Local application of antifungal agents such as Tolnaftate and application of selenium sulfide shampoo over affected area skin 5 to 20 minutes daily for 1-2 weeks are useful along with good skin hygiene.

Prognosis-

- ▶ Repeated attacks are commonly found.
- 