

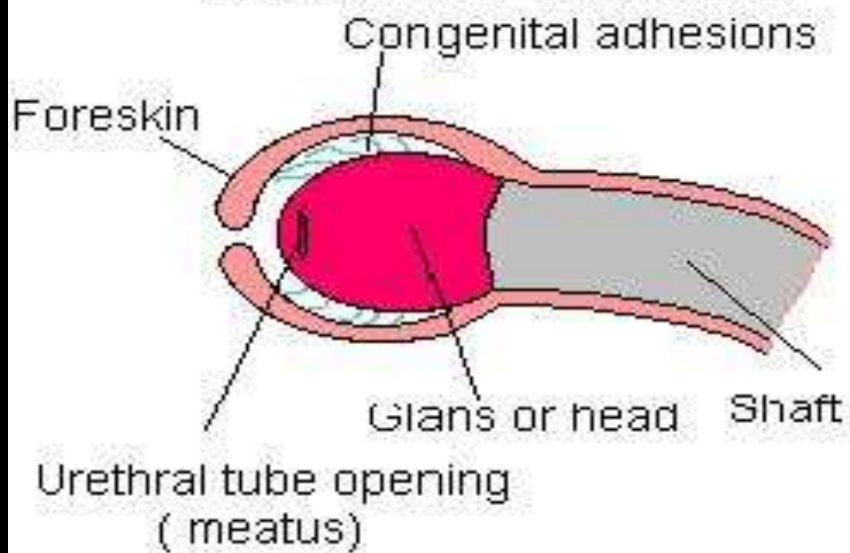


# PHIMOSIS

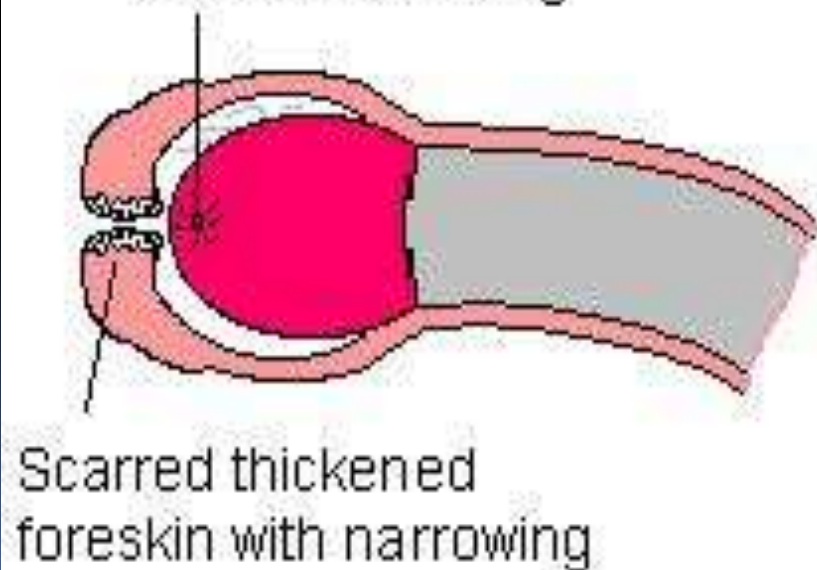
Narrowing or stenosis of preputial opening of foreskin



# NORMAL FORESKIN



# Meatal narrowing



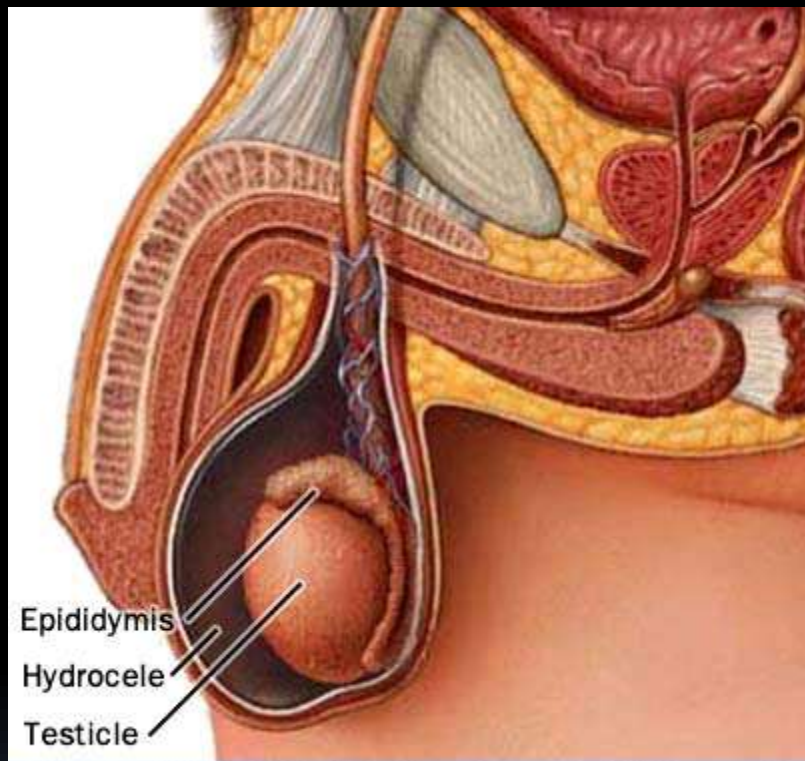


# Management

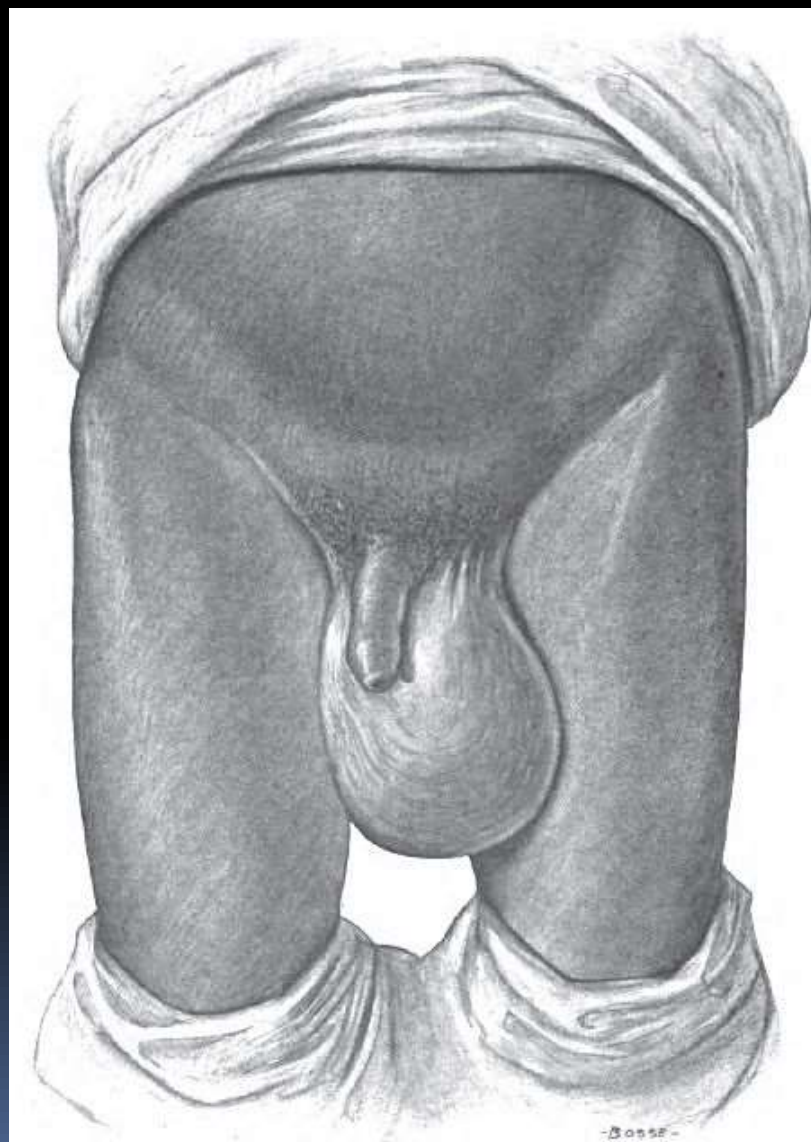
- Mild cases: manual retraction of foreskin & proper cleansing of area
- Severe cases: circumcision or vertical division & transverse suturing of foreskin.

# HYDROCELE


- Fluid in scrotum
- A hydrocele is a collection of straw colored & odorless fluid in the tunica vaginalis of the testicle or along the spermatic cord.



© Mayo Foundation for Medical Education and Research. All rights reserved.



- It is caused by failure of the processus vaginalis to be obliterated, the same problem that leads to inguinal hernia.
- Two types:
  - Non communicating: requires no treatment. Fluid usually absorbed spontaneously.
  - Communicating: if a hydrocele is associated with inguinal hernia or if it persists after 1 yr of age, surgical closure is necessary.

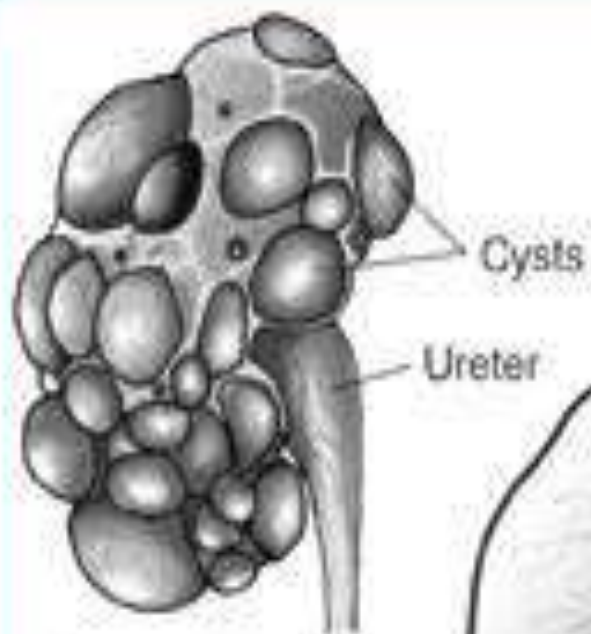


**POLYCYSTIC KIDNEY  
DISEASE  
OR  
CONGENITAL  
POLYCYSTIC KIDNEYS**

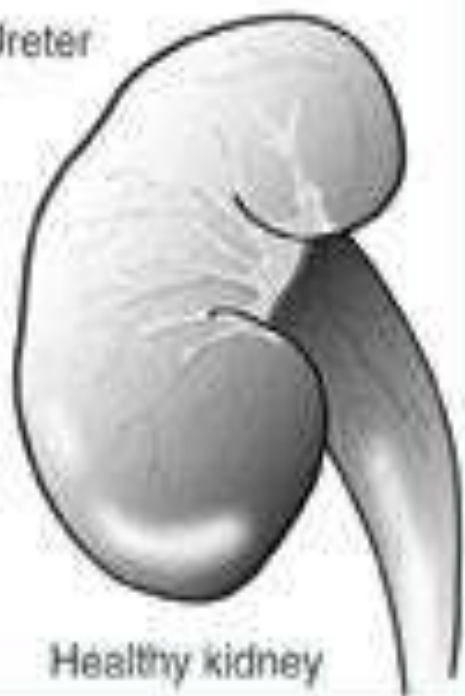# Definition

- In the neonate, the kidneys are grossly enlarged & filled with cysts of varying sizes. The cysts are dilated distal tubules and collecting ducts.
- Usually unilateral
- As the child grows, renal lesions are the same qualitatively, but quantitatively there is a difference.





Polycystic kidney



Healthy kidney

## Clinical features:

- Abdominal distention
- On palpation both kidneys are generally found to be enlarged.
- May be anuria or oliguria
- Hematuria
- Severe growth disturbances may occur.

## Diagnosis:

- X- rays
- Intravenous urography
- Urine examination
- Liver biopsy in older children




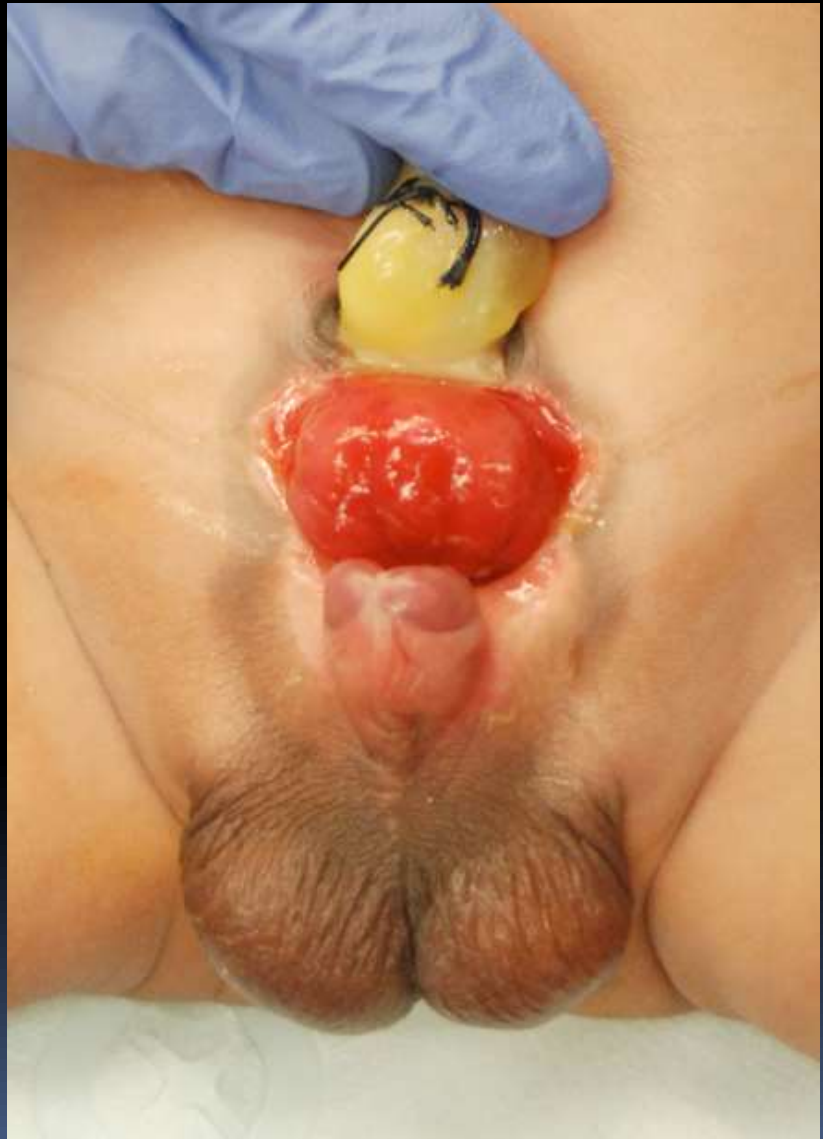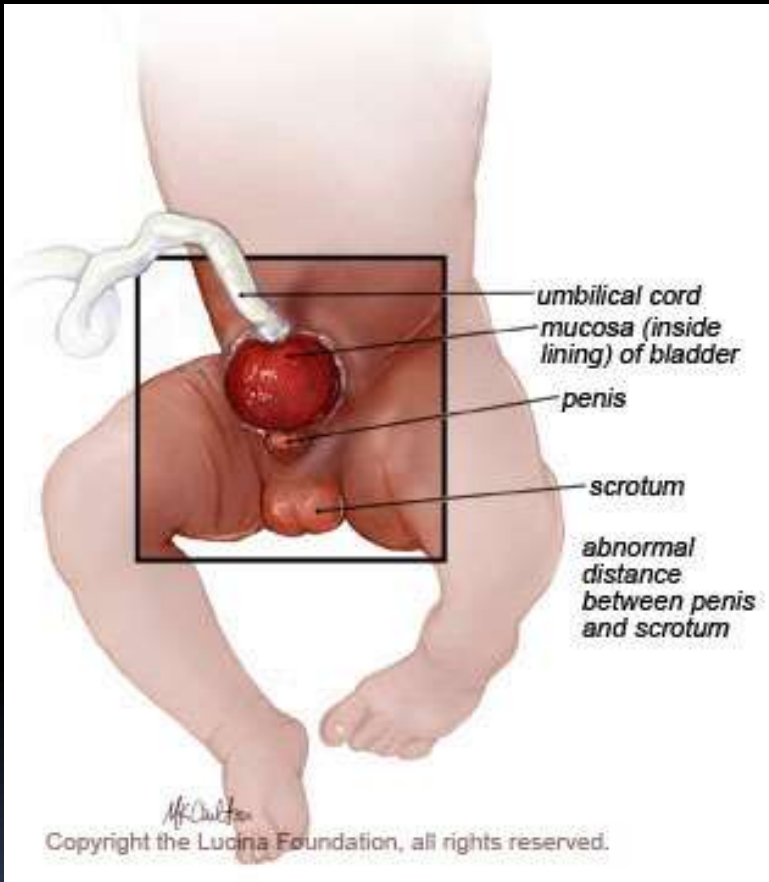
# Management

- There is no specific treatment
- In older children steps are taken to control HTN
- Supportive & palliative measures may be used in treatment of CRF
- Dialysis & renal transplantation may become necessary.

# EXSTROPHY OF BLADDER



- 
- It results when an abnormally large cloacal membrane prevents mesodermal ingrowth & lower abdominal midline fusion.
  - When cloacal membrane ruptures, the anterior abdominal wall, pubis, bladder & urethra fail to develop normally.
  - Complete exstrophy is an extensive anomaly
  - This defect in male infant may be accompanied by short, broad, spade like penis, epispadias, undescended testes or inguinal hernia.



s/s:

- Exstrophy
- Constant odor of urine & excoriation of the surrounding skin due to seeping of urine onto the posterior bladder wall from the abnormal urethral outlets.
- Ulceration of bladder mucosa.
- Infection leads to progressive renal damage & ultimate renal failure.

Diagnosis: urogram


# Management

- Surgical correction may not be undertaken immediately.
- A bland ointment may be applied around the bladder area to shield the skin against draining urine.
- The infant's clothing should be loose & light weight to avoid pressure on the exposed bladder wall.
- If the exstrophy is not complete, the abdominal & bladder walls may be closed by plastic surgery.
- Closure of the bladder with urinary diversion may be necessary.



# Nursing management

- Parents must be taught the general care of the infant before discharge
- Teach parents to keep the bladder area very clean & to cover it with sterile petroleum gauze to prevent infection & possible ulceration.
- The diaper should be changed frequently for the infant's comfort & to prevent constant odor of urine.

- 
- Stool is removed immediately so that it does not contaminate the bladder mucosa.
  - Teach parents that the infant should not be immersee in water at bath time because of the risk of contamination of ureters & bladder wall.
  - If a urine specimen is to be obtained, it is collected from the opening in the bladder with a medicine dropper or a syringe.
  - Include parents & child if older in pre operative teaching.

# Post operatively

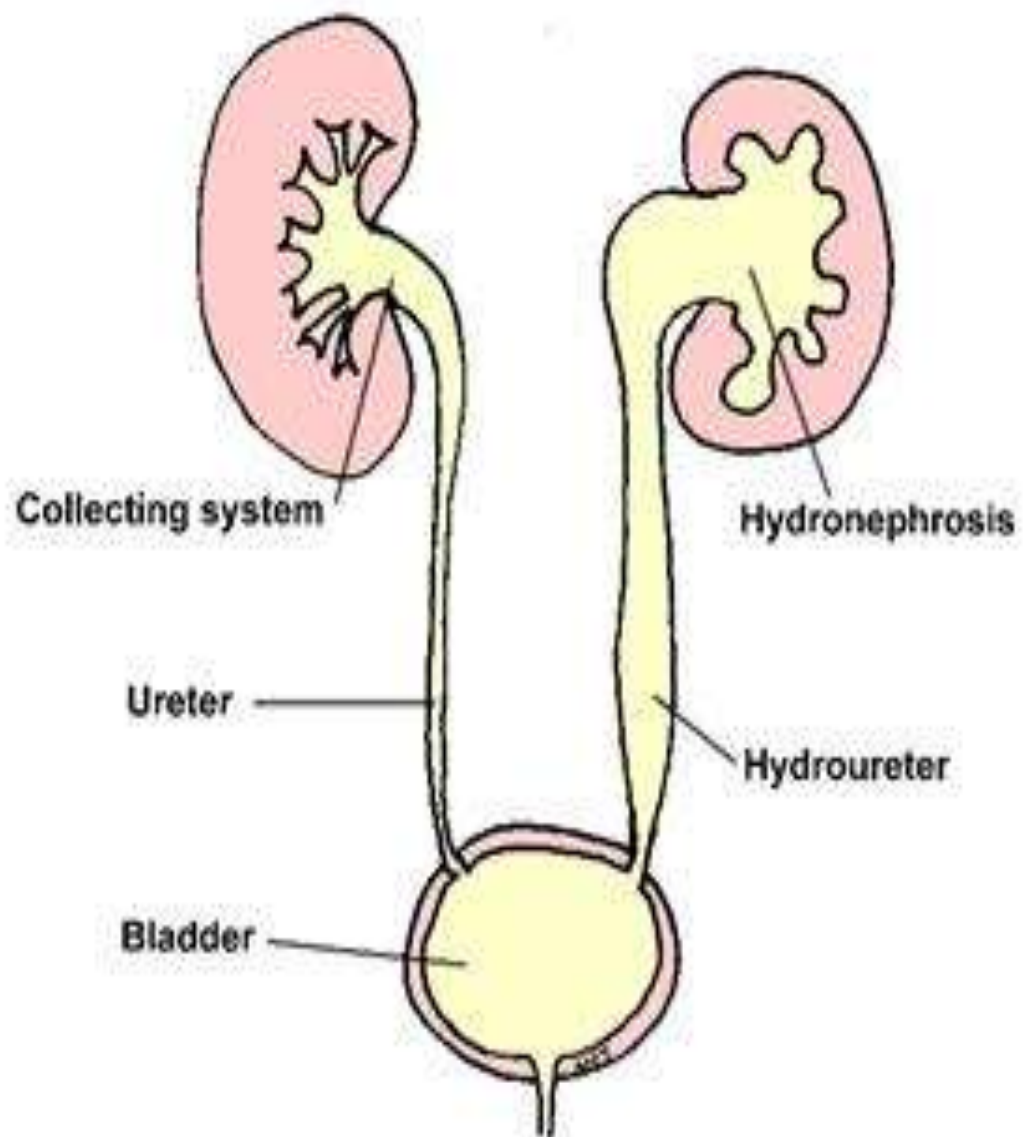
- Same as any other surgery
- Abdominal dressings must be kept clean & dry
- Child is positioned in such a way as to prevent kinking of any drainage tubing.
- Teach parents about importance of adequate fluid intake.
- Antibiotic therapy
- If child develops fever, hematuria or purulent drainage from the incision, the physician should be notified.




# HYDRONEPHROSIS


It is a dilation of the kidney collecting system





- 
- It can be found on ultrasounds and X rays.
  - Causes:
    1. Ureteropelvic junction obstruction
    2. Congenital/ non obstructive hydronephrosis
    3. Vesicoureteral reflux


### Management :

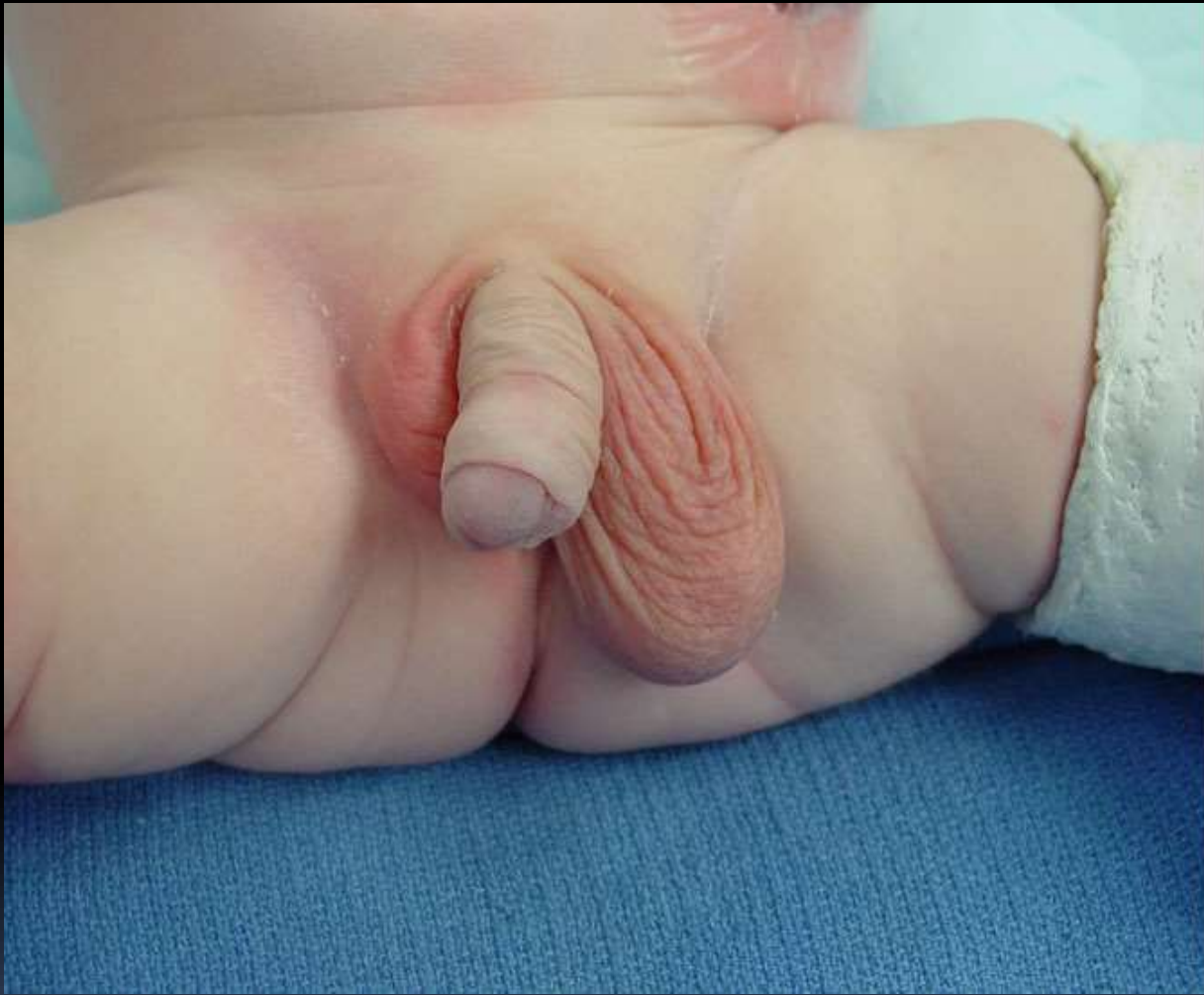- Some children have spontaneous resolution.
  - Surgery: open pyeloplasty
- 



# CRYPTORCHIDISM

Failure of the one or both testes to descend normally through inguinal canal.

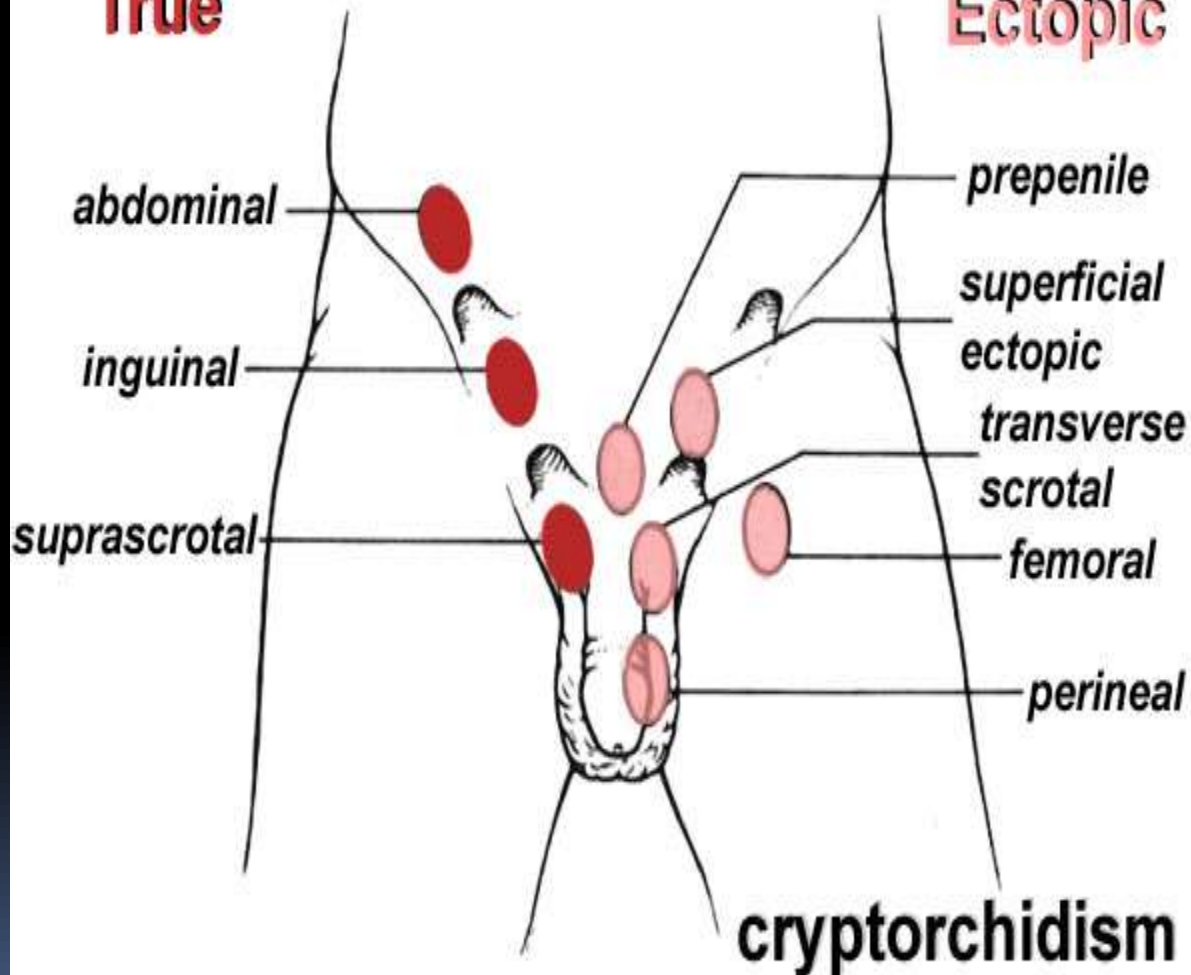






**True**

**Ectopic**



abdominal

inguinal

suprascrotal

prepenile


superficial  
ectopic

transverse  
scrotal

femoral

perineal

**cryptorchidism**

- 
- Detected by inability to palpate testes in scrotum.
  - Med: administration of HCG (older child)
  - Surg: orchiopexy
- 