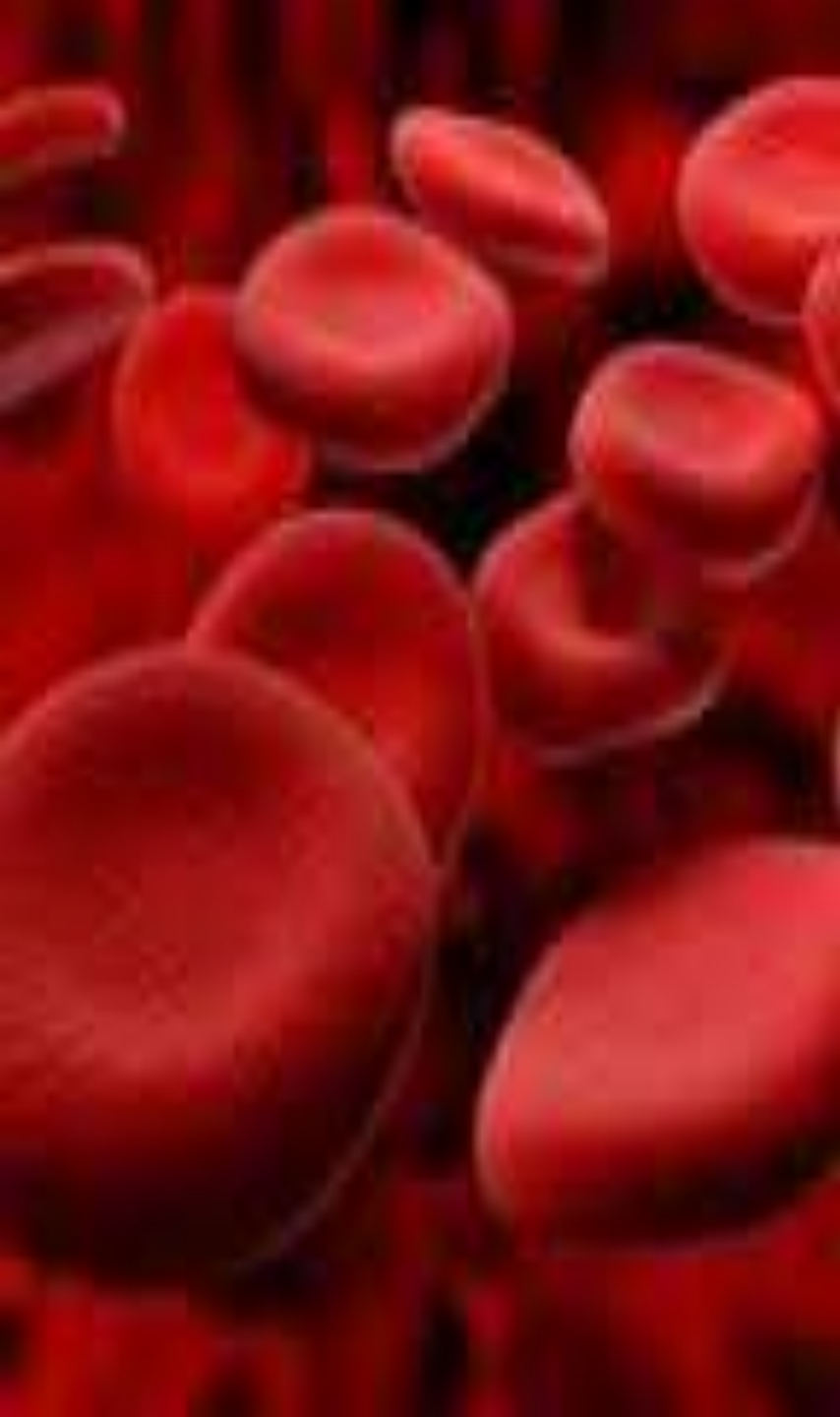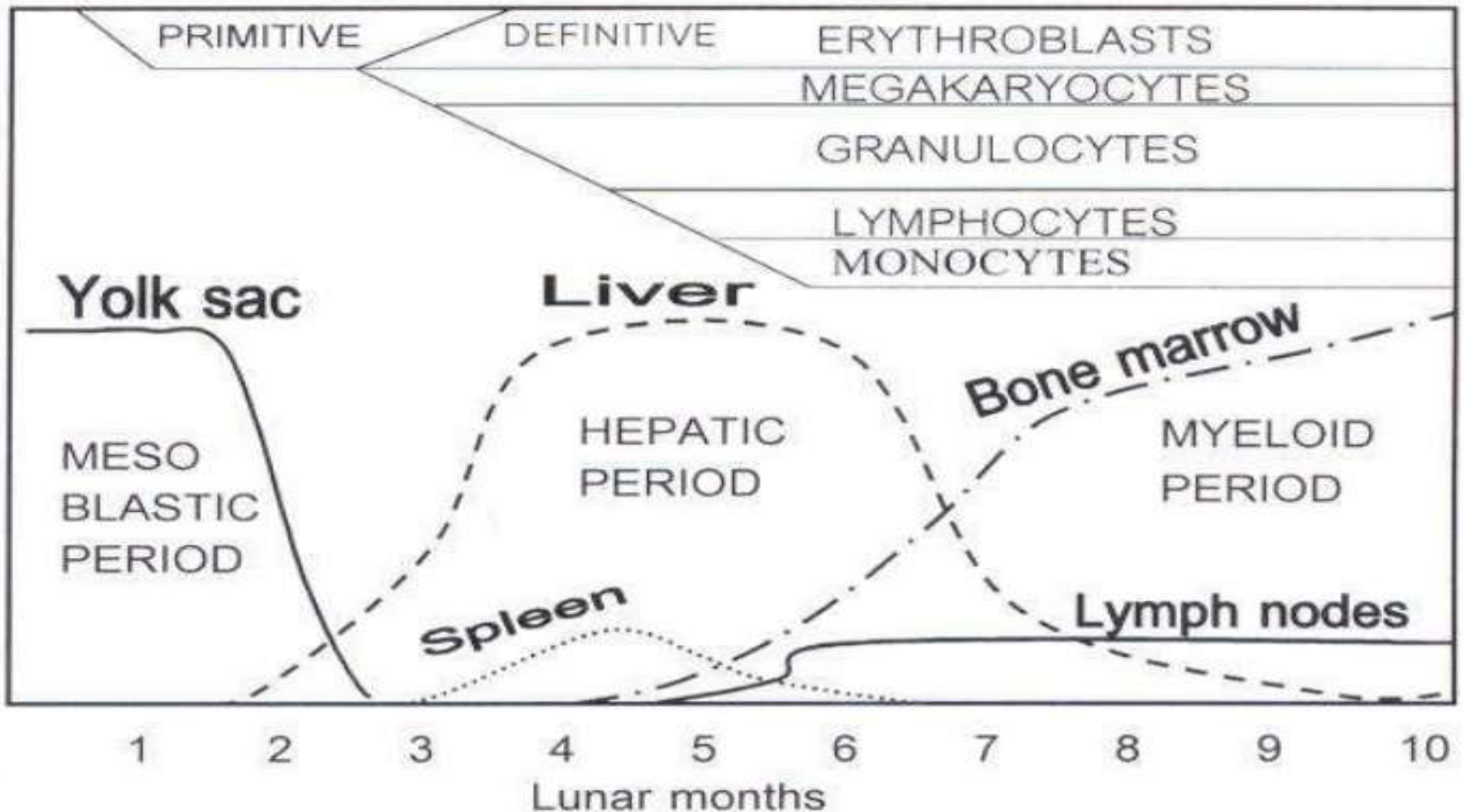




HEMOLYTIC DISEASES OF NEWBORN

EMBRYONIC DEVELOPMENT










INTRODUCTION:

Four blood types (A, B, AB, and O)

Each blood type is additionally classified according to the presence or absence of the Rh factor

The ABO Blood System

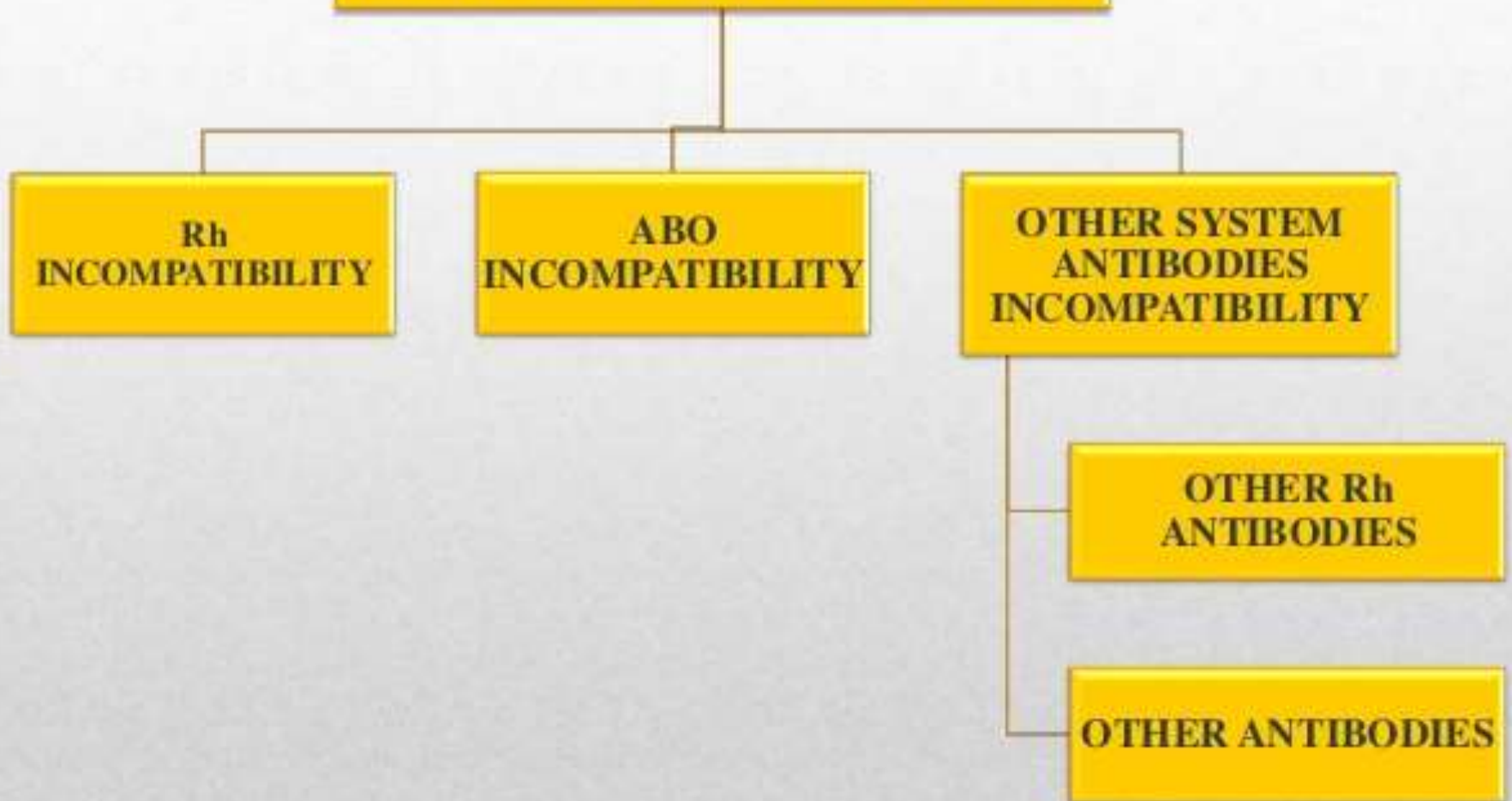
Blood Type (genotype)	Type A (AA, AO)	Type B (BB, BO)	Type AB (AB)	Type O (OO)
Red Blood Cell Surface Proteins (phenotype)	 A agglutinogens only	 B agglutinogens only	 A and B agglutinogens	 No agglutinogens
Plasma Antibodies (phenotype)	 b agglutinin only	 a agglutinin only	NONE. No agglutinin	 a and b agglutinin

DEFINITION

A condition in which fetus or neonate's red blood cell (RBC) are destroyed by Immunoglobulin G (IgG) antibodies produced by mother.

- "hemolytic" means breaking down of red blood cells
 - "erythroblastosis" refers to making of immature red blood cells
 - "fetalis" refers to fetus
-

CAUSES OF HDN



CAUSES OF HDN

1) Rh incompatibility

- HDN is occurred when a mother with Rh-negative blood becomes pregnant with Rh-positive baby that inherited from Rh-positive father.
- It occurs when anti-D is stimulated in mother plasma due to mother 's immune response to the antigen D on fetal's red blood cells.
- This is due to anti-D is an IgG that capable to cross placenta and hence delivered to fetal circulation.
- Rh caused HDN is less common but more severe.

2) ABO incompatibility

- HDN is arouse when a mother with blood type O becomes pregnant with a fetus with different blood types A, B or AB.
- ABO antibodies is natural occurring antibodies that clinically significant.
- ABO caused HDN is commonly occur but less severe.

RH INCOMPATIBILITY (ERYTHROBLASTOSIS FETALIS)



Definition

Erythroblastosis Fetalis is a *hemolytic anemia* in the fetus or neonate, caused by trans-placental transmission of maternal antibodies to fetal RBCs. The disorder usually results from incompatibility between maternal and fetal *blood groups*, often *Rh antigens*.

- ⦿ If a Rh- mother becomes pregnant by a Rh+ father and If baby is Rh+
- ⦿ This means a Rh+ baby growing in a Rh- mother.
- ⦿ At the time of birth some of the baby's blood gets into the mother's circulation.



Rh -




Rh +



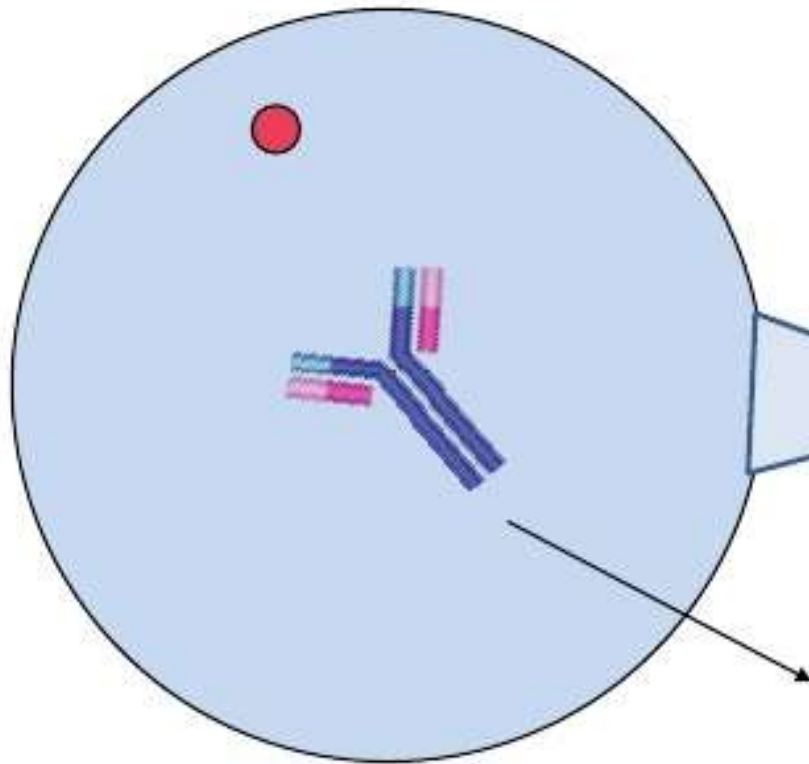
Rh +

At the time of delivery




Rh + cells from foetus enters mother

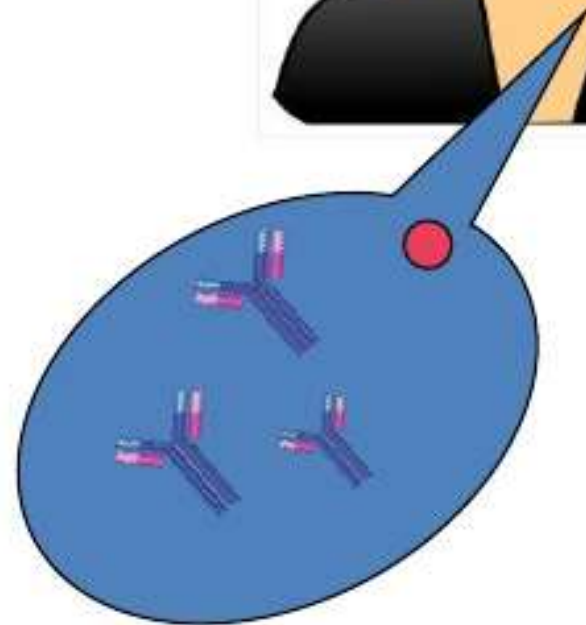
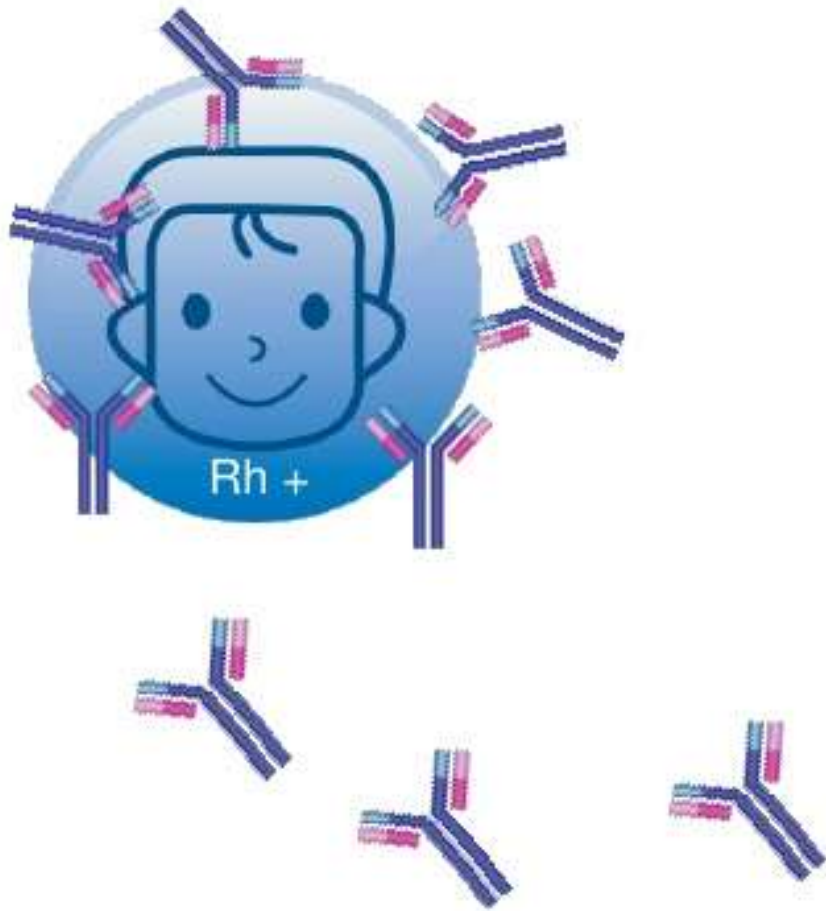
Mother's immune system



**Mother develops antibodies
to Rh + cells from foetus**

Second Pregnancy





Antibodies to Rh + cells enter foetal circulation

ASSESSMENT

- ⊙ The colour of amniotic fluid.
 - Fluid if straw colored – not affected.
 - Deep yellow- severely affected.
 - Brown or green- extremely ill or still born.
- ⊙ Clinical features
 - ✓ Pallor
 - ✓ Jaundice
 - ✓ Hydrops
 - ✓ hepatosplenomegaly

LABORATORY FEATURES

- ⦿ Blood type
- ⦿ Anemia
- ⦿ Direct coomb's test- positive
- ⦿ Indirect coomb's test- negative
- ⦿ Hyperbilirubinemia
- ⦿ RBC morphology- Nucleated RBC's.

ABO INCOMPATIBILITY OF HDN

- ABO HDN is due to incompatibility of ABO between mother and fetus.
 - A portion of the mother's ABO antibodies may be IgG and cross the placenta.
 - It thus sensitizes the fetal cells.
 - This condition can occur on the first pregnancy and can occur without there having been transfusion.
 - The mechanism of ABO HDN is similar to the RH HDN.
 - Occurrence of ABO HDN is somewhat common, but fortunately it is not often very severe.
-

⊙ CLINICAL FEATURES

- Pallor-minimal
- Jaundice-minimal to moderate.
- Hydrops-rare
- Hepatosplenomegaly-minimal

➤ LABORATORY FEATURES

- ⊙ Blood type
- ⊙ Anemia
- ⊙ Direct coomb's test- NEGATIVE
- ⊙ Indirect coomb's test- POSITIVE
- ⊙ Hyperbilirubinemia- variable
- ⊙ RBC morphology- spherocytes.

MANAGEMENT

- ⊙ Phototherapy.
- ⊙ Exchange transfusion
- ⊙ Emotional support.
- ❖ Prevention

ANEMIA

- Once antigen-antibody interaction occurs, antibody-coated red blood cells are removed from fetal circulation by macrophages of the spleen and liver which lead to anemia
- Anemia limits the ability of the blood to carry oxygen to the baby's organs and tissues.

ORGAN ENLARGEMENT

- In response to anemia, fetal bone marrow and other hematopoietic tissues in the spleen and liver increase the amount of red blood cells production.
- Baby's responds to the hemolysis by trying to make more red blood cells very quickly in the bone marrow and the liver and spleen.
 - Organs enlarge - hepatosplenomegaly.
 - New red blood cells released prematurely from bone marrow and are unable to do the work of mature red blood cells produced many nucleated red blood cell which is unable to carry oxygen.

HYPERBILIRUBINEMIA

- As the red blood cells break down, bilirubin is formed
- Accumulation of bilirubin in body tissue and fluid results in jaundices.
- Due to immature liver of the newborn and inability to conjugated the unconjugated bilirubin result in the unconjugated bilirubin increasing and crossing the blood brain barrier and cause kernicterus.

A microscopic view of numerous red blood cells, which are biconcave discs, filling the frame. The cells are a vibrant red color and are scattered across the field of view, some in sharp focus and others blurred in the background. The word "ANEMIA" is superimposed in the center in a white, stylized font.

ANEMIA

DEFINITIONS

- ⦿ Anemia: Central venous hemoglobin < 13 g/dL or capillary hemoglobin < 14.5 g/dL in infant > 34 weeks and 0-28 days old
- ⦿ Average value for central venous hemoglobin at birth for > 34 weeks GA is 17 g/dL
- ⦿ Reticulocyte count in cord blood 3-7%
- ⦿ Average mean corpuscular volume 107 fL

PATHOPHYSIOLOGY

- ⊙ Anemia in the newborn results from three processes
 - Blood Loss: Hemorrhagic anemia
 - Shortened RBC life span: Increased destruction: hemolytic anemia
 - Underproduction of RBCs: hypoplastic anemia

BLOOD LOSS

- ⊙ Obstetric causes of blood loss.
- ⊙ Occult blood loss before or during delivery.
- ⊙ Bleeding in the neonatal period.

HEMOLYSIS

- ⊙ Immune hemolytic anemia
- ⊙ Maternal auto immune hemolytic disease.
- ⊙ Non-immune hemolytic anemia in the newborn.

❖ **INADEQUATE RBC PRODUCTION**

- Clinical manifestations
- Diagnosis
- Management
- Prevention

HEMORRHAGIC DISEASE OF THE NEWBORN



HAEMORRHAGIC DISEASES OF THE NEWBORN

It is a syndrome characterized by spontaneous internal or external bleeding. In neonates, there is decreased activity of several clotting factors and diminished platelet function.



CAUSES

- **Abnormalities of clotting factors**

- Deficiencies of vitamin k dependent factors – II, VII, IX, X. it usually occurs between D2 and D5 and common in preterm and breast fed babies. Deficiency of protein C is also responsible
- Drugs – received by mother during pregnancy – phenytoin, coumarin compounds, salicylates (affects vit K function).
- **DIC** – due to infection, Anoxia, shock.



2. Disturbances of clotting

- Related to DIC due to infection, shock, anoxia, NEC, renal vein thrombosis, use of IV canula.

3. Inherited abnormalities of C.F.

a. X-LINKED RECESSIVE DISEASES-

- i. Hemophilia-A : Factor VIII deficiency.
- ii. Hemophilia-B : Factor IX deficiency.

COMMON CLINICAL MANIFESTATIONS

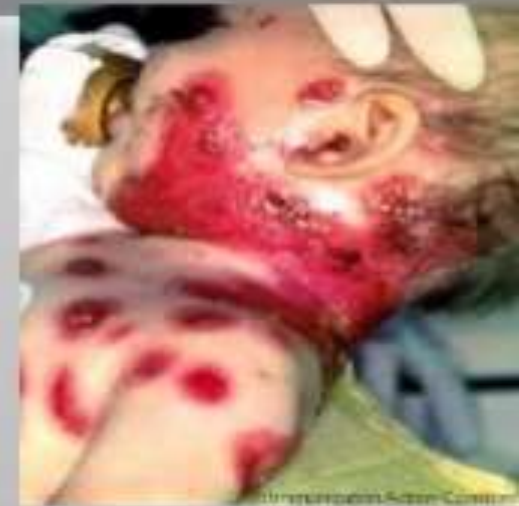- ◎ **Bleeding in the**
 - **gastrointestinal tract**
 - **urinary tract**
 - **umbilical stump**
 - **nose**
 - **scalp**
 - **intracranial hemorrhage**
 - **Shock**
 - **death**



DIAGNOSTIC WORKUP

A. History

- Family h/o bleeding disorders
- Maternal medications
- Pregnancy & birth history
- Maternal h/o infant with bleeding disorder
- Any medications, procedures, anomalies in infant





B. Examination:

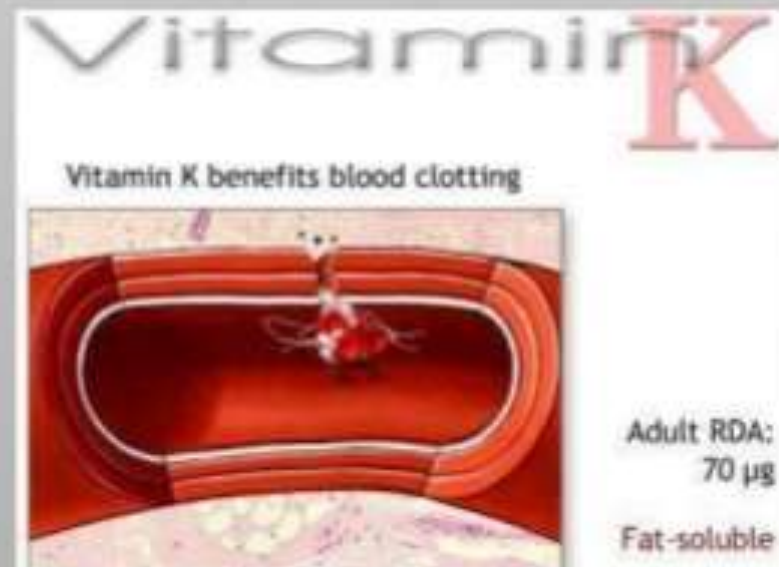First diagnose whether the infant is Sick or Well

1. Sick infant:

- DIC
- Bacterial/ viral infections.

2. Well infant:

- Vit K deficiency
- Isolated C.F. deficiencies
- Immune thrombocytopenia
- Maternal blood in infant's GIT.





3. Patchiae, ecchymosis, mucosal bleeding:
Platelet problem
4. Large bruises: DIC, C.F deficiencies, liver diseases
5. Enlarged spleen : Possible congenital infections or erythroblastosis.
6. Jaundice : Sepsis, liver diseases, resorption of large hematoma.

⊙ Management

⊙ Outcome

⊙ Prevention